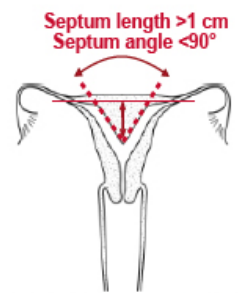
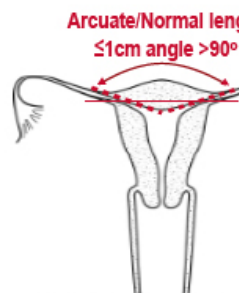
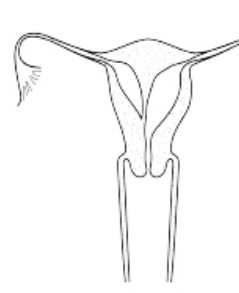
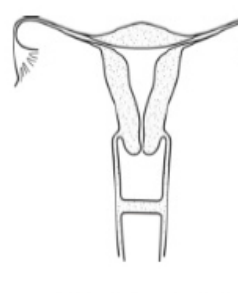
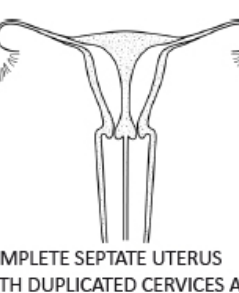


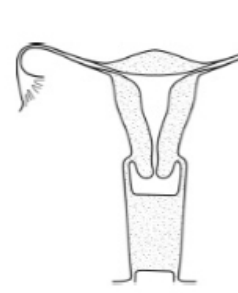


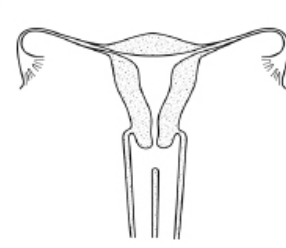
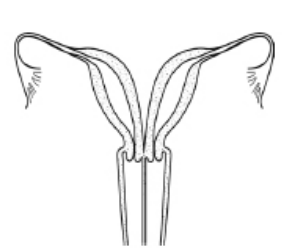
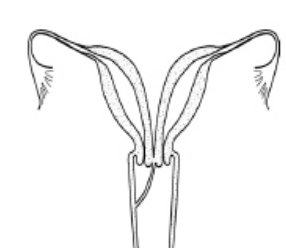
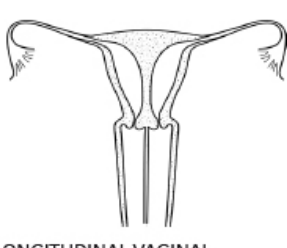
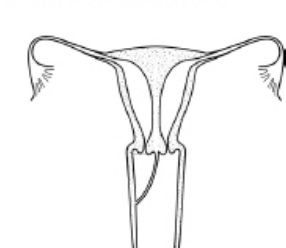

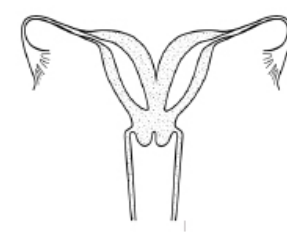
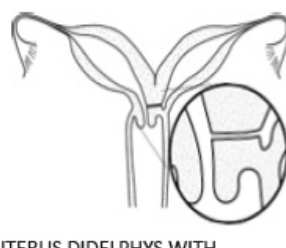
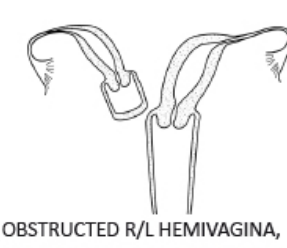
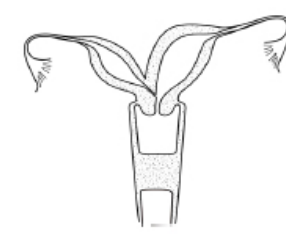
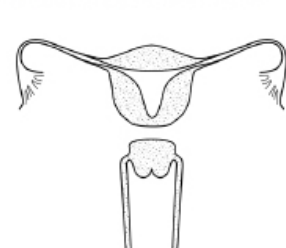


UpToDate[®]

Official reprint from UpToDate[®]
www.uptodate.com © 2025 UpToDate, Inc. and/or its affiliates. All Rights Reserved.

ASRM müllerian anomalies classification 2021 (page 2 of 2)

SEPTATE UTERUS			TRANSVERSE VAGINAL SEPTUM
 <p>Septum length >1 cm Septum angle <90°</p> <p>PARTIAL SEPTATE UTERUS</p>	 <p>Arcuate/Normal length ≤1cm angle >90°</p> <p>NORMAL/ARCUATE UTERUS</p>	 <p>ROBERT'S UTERUS</p>	 <p>MID VAGINAL SEPTUM</p>
 <p>COMPLETE SEPTATE UTERUS WITH DUPLICATED CERVICES AND LONGITUDINAL VAGINAL SEPTUM</p>	 <p>COMPLETE SEPTATE UTERUS WITH SEPTATE CERVIX AND LONGITUDINAL VAGINAL SEPTUM</p>	 <p>COMPLETE SEPTATE UTERUS, DUPLICATED CERVICES, AND OBSTRUCTED R/L HEMIVAGINA</p>	 <p>DISTAL VAGINAL AGENESIS</p>

LONGITUDINAL VAGINAL SEPTUM	COMPLEX ANOMALIES
 <p>LONGITUDINAL VAGINAL SEPTUM OF VARIABLE LENGTH</p>	 <p>LONGITUDINAL VAGINAL SEPTUM OF VARIABLE LENGTH AND UTERUS DIDELPHYS</p>
 <p>OBSTRUCTED R/L HEMIVAGINA AND UTERUS DIDELPHYS</p>	 <p>LONGITUDINAL VAGINAL SEPTUM OF VARIABLE LENGTH AND COMPLETE SEPTATE UTERUS WITH DUPLICATED CERVIX</p>
 <p>OBSTRUCTED R/L HEMIVAGINA AND COMPLETE SEPTATE UTERUS WITH DUPLICATED CERVICES</p>	<div style="text-align: center;">  <p>Scan QR code to view the ASRM MAC 2021 tool (page 2 of 2) ©2021 American Society for Reproductive Medicine</p> </div>
	 <p>BICORNUATE UTERUS WITH BILATERAL OBSTRUCTED ENDOMETRIAL CAVITIES</p>
	 <p>UTERUS DIDELPHYS WITH COMMUNICATING HEMIUTERI AND UNILATERAL R/L CERVICO-VAGINAL ATRESIA</p>
	 <p>OBSTRUCTED R/L HEMIVAGINA, HEMIUTERUS AND SINGLE CERVIX WITH SEPARATE CONTRALATERAL R/L PATENT HEMIUTERUS, CERVIX AND VAGINA</p>
	 <p>BICORNUATE UTERUS WITH R/L COMMUNICATING TRACT AND TRANSVERSE VAGINAL SEPTUM</p>
	 <p>UTERUS ISTHMUS AGENESIS</p>

ASRM: American Society for Reproductive Medicine; R/L: right- or left-sided.

Reproduced with permission. Copyright © 2021 American Society for Reproductive Medicine. Available at: <https://connect.asrm.org/education/asrm-mac-2021> (Accessed on April 14, 2023). Corresponding article: Pfeifer SM, Attaran M, Goldstein J, et al. ASRM müllerian anomalies classification 2021. *Fertil Steril* 2021; 116:1238.

